Case Report

# Restrictive Cardiomyopathy and Complete Atrioventricular Block Associated With a Genetic Variant in the Desmin Gene

*Fernando Almeida Bezerra,[1] Matheus Martins,[2] Moisés Abtibol Machado,[1] Denison Clark Correa de Miranda,[1] Monica Gonçalo,[1] Katia do Nascimento Couceiro,[1] Bianca Domit Wener Linnenkamp,[3] Emanuelle Leonilia Marques,[3] José Eduardo Krieger,[3] João Marcos Bemfica Barbosa Ferreira[1]*

*Universidade do Estado do Amazonas,[1] Manaus, AM – Brazil*
*Beneficencia Portuguesa de São Paulo,[2] São Paulo, SP – Brazil*
*Instituto do Coração do Hospital das Clínicas da Faculdade de Medicina da Universidade de São Paulo (InCor-HCFMUSP),[3] São Paulo, SP - Brazil*

## Introduction

Restrictive cardiomyopathy is an uncommon cardiac condition characterized by severe diastolic dysfunction, increased ventricular stiffness, and atrial enlargement. This condition may lead to the development of heart failure, often with preserved ejection fraction, and is associated with a high mortality rate. Both genetic and nongenetic factors play a role in restrictive cardiomyopathy, and a significant proportion of cases have an unknown etiology. However, the genetic forms of this disease and the molecular mechanisms involved are only partially understood.[1]

Desmin deposition-associated restrictive cardiomyopathy is a rare genetic condition involving desmin, an intermediate filament protein expressed in cardiac, skeletal, and smooth muscle. This disorder is characterized by the presence of granulofilamentous deposits that are immunoreactive for desmin within the cytoplasm of cardiomyocytes. In addition to impairing ventricular filling during diastole, patients often present with skeletal myopathy, and varying degrees of atrioventricular conduction block are also common. This conduction abnormality may range from mild conduction delay (first- and second-degree atrioventricular block [AVB]) to complete interruption of electrical communication between the atria and ventricles, known as complete atrioventricular block (CAVB) or third-degree AVB.[2,3]

The most common symptoms include dyspnea, edema, palpitations, and jugular venous distention. Although the diagnosis may be established by echocardiography, additional imaging modalities, such as computed tomography and cardiac magnetic resonance imaging, are often required for differential diagnosis, particularly to distinguish the condition from constrictive pericarditis.[4]

## Keywords

Restrictive cardiomyopathy; Desmin; Desmin; Complete atrioventricular block.

**Mailing Address: Matheus Martins •**
Beneficência Portuguesa de São Paulo. R. Maestro Cardim, 637. Postal code: 01323-900. Bela Vista, São Paulo, SP – Brazil
E-mail: matheussmartins.1996@gmail.com
Manuscript received December 15, 2025; revised manuscript January 2, 2026; accepted August 3, 2026.
Editor responsible for the review: Ricardo Alkmim Teixeira

**DOI:** https://doi.org/10.36660/ijcs.20250293

The objective of this case report is to describe a case of restrictive cardiomyopathy and CAVB associated with a genetic variant in the desmin gene, with the primary aim of highlighting the importance of accurate diagnosis and appropriate treatment while addressing the controversial aspects and limited data regarding this specific condition. This patient is part of a broader research project approved by the Research Ethics Committee of the Universidade do Estado do Amazonas under approval number 7.108.530 and CAAE 55200322.5.3009.516.

## Case report

A 17-year-old girl from Óbidos, Pará, Brazil, was referred to a specialized cardiomyopathy clinic. She reported episodes of fainting and syncope since the age of 14, with worsening approximately 2 years prior to presentation, when she was evaluated in Santarém with a heart rate of 32 beats/min (according to the patient's report). She denied any musculoskeletal symptoms. At that time, an electrocardiogram (ECG) was performed and demonstrated CAVB (Figure 1). She was subsequently referred to Manaus, where a dual-chamber permanent pacemaker was implanted. Figure 2 shows another ECG of the patient, obtained before the episode of CAVB, demonstrating sinus rhythm with biatrial enlargement, left bundle branch block (QRS = 120 milliseconds), and a corrected QT interval of 421 milliseconds.

At that time, transthoracic echocardiogram also revealed preserved left ventricular systolic function (left ventricular ejection fraction = 73%), moderate biatrial enlargement (indexed left atrial volume of 46 mL/m$^2$), mild pulmonary hypertension (pulmonary artery systolic pressure = 41 mmHg), an E/A ratio of 4.7, and a lateral E/E′ ratio of 15. These findings were consistent with grade III left ventricular diastolic dysfunction and suggestive of restrictive cardiomyopathy (Figure 3).

Following pacemaker implantation, the patient had an uneventful postoperative course, with no significant complications. She was discharged in improved clinical condition and continued outpatient follow-up for medical management. She remained asymptomatic thereafter.

At subsequent visits to the specialized cardiomyopathy clinic, the patient remained asymptomatic. ECG demonstrated normally functioning pacemaker activity and showed the same previously described abnormalities. Cardiac magnetic resonance imaging was not performed because of limited local availability and considerations related to the implanted cardiac device.

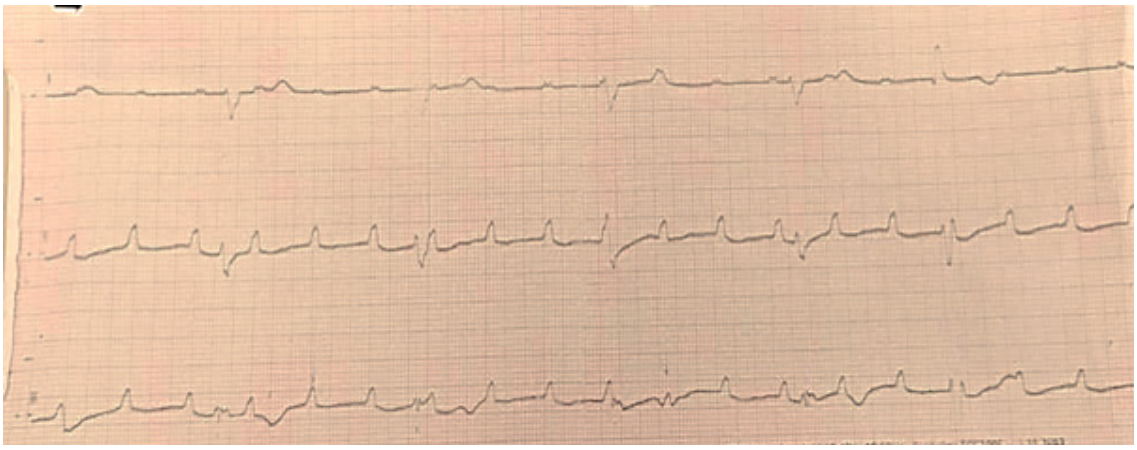

**Figure 1 –** *ECG demonstrating CAVB and peaked P waves in leads II and III, suggestive of right atrial enlargement.*

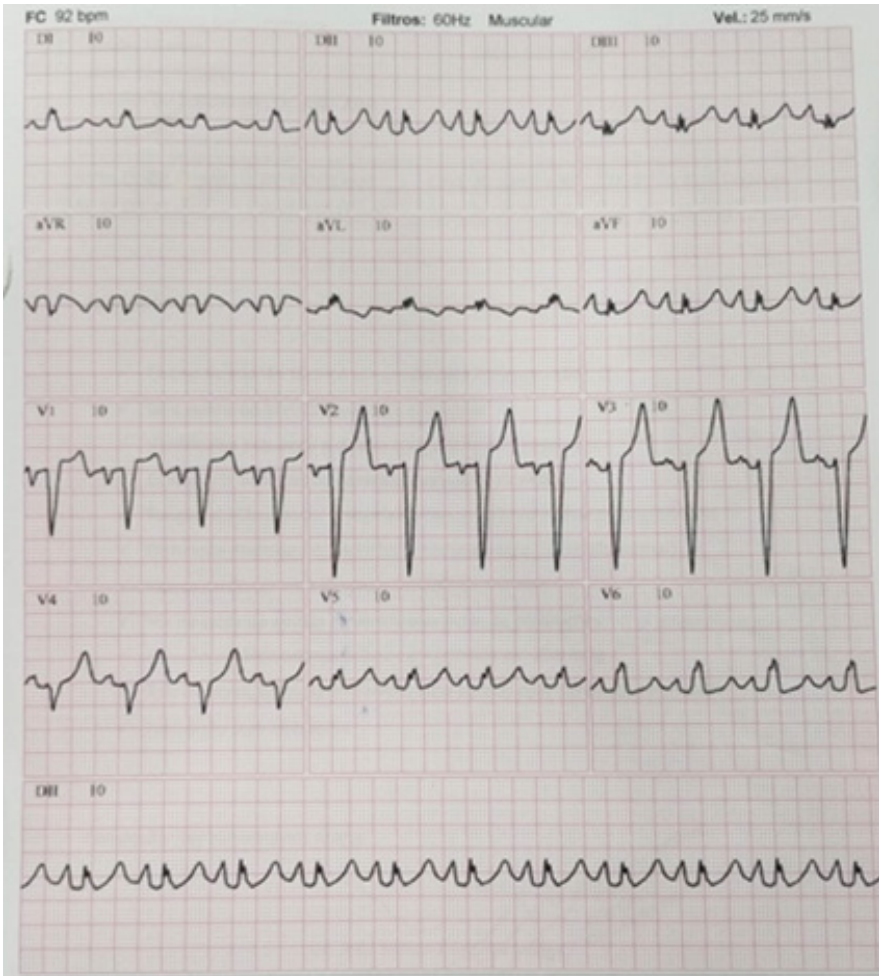


**Figure 2 –** *ECG obtained before the episode of CAVB showing sinus rhythm, biatrial enlargement, heart rate of 92 beats/min, left bundle branch block (QRS = 120 milliseconds), and a corrected QT interval of 421 milliseconds.*

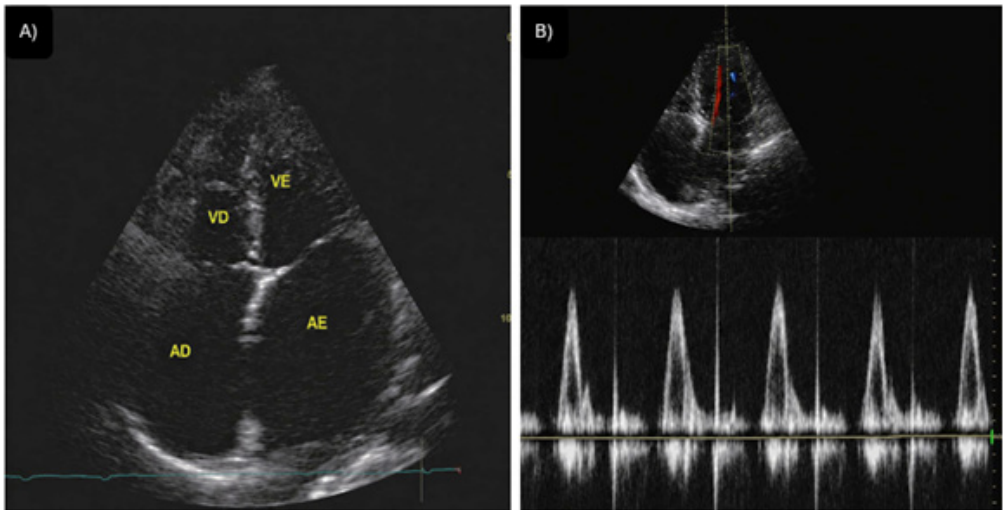


**Figure 3 –** *A) Transthoracic echocardiogram demonstrating biatrial enlargement; B) Pulsed-wave Doppler of mitral inflow demonstrating a restrictive filling pattern.*

Genetic testing identified a heterozygous variant, NM_001927.4:chr2.219425671 C > A (p.Pro433Thr), in the desmin (DES) gene. Although the clinical phenotype was consistent with desmin-related cardiomyopathy, the identified variant remains classified as a Variant of Uncertain Significance (VUS), and a definitive causal relationship could not be established. The patient remained under clinical observation and outpatient follow-up, and family screening is ongoing.

Family screening included the patient's father and brother, neither of whom was found to carry the same genetic variant to date. It should be noted that the patient is from the state of Pará and undergoes annual follow-up at our referral center in the state of Amazonas, which limits the extent of family screening and comprehensive genetic assessment of other relatives.

## Discussion

Restrictive cardiomyopathy may occur as an idiopathic or hereditary condition or as a consequence of systemic disorders, such as amyloidosis, sarcoidosis, and hereditary hemochromatosis. Approximately 30% of cases are familial. Genes associated with the condition include TNNT2, TNNI3, MYBPC3, MYH7, MYL2, MYL3, MYPN, TTN, BAG3, DCBLD2, LMNA, and FLNC, in addition to DES. Desmin-related myopathies, resulting from the accumulation of desmin within the cytoplasm, are classified as primary desminopathies caused by mutations in the desmin gene.[5]

The clinical manifestations of primary desminopathies encompass a broad spectrum, ranging from skeletal muscle and cardiac disorders to specific cardiac phenotypes, including dilated cardiomyopathy and desmin accumulation in restrictive cardiomyopathy associated with AVB. Neuromuscular symptoms may coexist in some cases; however, patients with an exclusively cardiac phenotype and no evidence of myopathy have also been reported. This presentation is similar to that observed in the patient described herein, who had no skeletal muscle symptoms.[6-8]

The study by Arbustini *et al*. also demonstrated that variants in the DES gene have been associated with specific cardiac phenotypes known as desminopathies. These phenotypes are characterized by restrictive cardiomyopathy and AVB in the absence of clinical signs of myopathy. Although the absence of myopathy may make it less likely for cardiologists to suspect desmin-related restrictive cardiomyopathy, further investigation for desmin accumulation should be considered once the most common cause of restrictive cardiomyopathy, cardiac amyloidosis, has been excluded and the restrictive phenotype is associated with AVB.[3]

Similar cases have been described by Cabral, Ruivo, and Martins[9] and by Jurcuţ *et al*.,[10] involving desmin-associated cardiomyopathy. In the latter report, the same genetic variant was identified. The identification of the same variant in an unrelated individual with a similar phenotype supports a possible genotype-phenotype association, although the variant remains classified as a VUS. This is a rare condition that is frequently associated with the need for pacemaker implantation for heart rate control. Similarities among the reported cases include episodes of syncope, AVB, and echocardiographic abnormalities.

In the present case, the clinical manifestations were consistent with restrictive cardiomyopathy associated with the identified variant in the desmin gene. The presence of conduction abnormalities is crucial to raising diagnostic suspicion. In this particular case, CAVB was the first manifestation identified. In addition, family screening may assist in the clinical assessment of affected individuals, as most disorders associated with DES variants and desmin accumulation follow an autosomal dominant inheritance pattern, although a minority are inherited in an autosomal recessive manner or result from de novo mutations. However, the family screening performed in this case was limited and insufficient to establish a robust genetic segregation analysis or a definitive causal relationship.[11-13]

## Conclusion

Among primary desminopathies, the most common classical phenotype is myopathy with or without cardiac involvement, a rare clinical phenotype characterized by restrictive cardiomyopathy and CAVB should raise suspicion of a DES-related disorder in cardiologists. The absence of any clinical signs of myopathy may obscure the diagnosis of desmin storage disease. Therefore, patients with non-amyloid restrictive cardiomyopathy and CAVB should undergo molecular analysis of the DES gene, which is an important differential diagnosis in this cardiac phenotype.

## Author Contributions

Conception and design of the research: Bezerra FA; acquisition of data: Bezerra FA, Martins M, Machado MA, Miranda DCC, Gonçalo M, Couceiro KN, Linnenkamp BDW, Marques EL, Krieger JE; writing of the manuscript: Bezerra FA, Martins M, Couceiro KN, Ferreira JMBB; critical revision of the manuscript for intelectual content: Ferreira JMBB.

### Potential Conflict of Interest

No potential conflict of interest relevant to this article was reported.

### Sources of Funding

There were no external funding sources for this study.

### Study Association

This study is not associated with any thesis or dissertation work.

### Ethics Approval and Consent to Participate

This study was approved by the Ethics Committee of the Universidade do Estado do Amazonas under the protocol number 7.108.530. All the procedures in this study were in accordance with the 1975 Helsinki Declaration, updated in 2013. Informed consent was obtained from all participants included in the study.

### Use of Artificial Intelligence

The authors did not use any artificial intelligence tools in the development of this work.

### Availability of Research Data

The underlying content of the research text is contained within the manuscript.

## References

1. Brodehl A, Gerull B. Genetic Insights into Primary Restrictive Cardiomyopathy. J Clin Med. 2022;11(8):2094. doi: 10.3390/jcm11082094.
2. Arbustini E, Morbini P, Grasso M, Fasani R, Verga L, Bellini O, et al. Restrictive Cardiomyopathy, Atrioventricular Block and Mild to Subclinical Myopathy in Patients with Desmin-Immunoreactive Material Deposits. J Am Coll Cardiol. 1998;31(3):645-53. doi: 10.1016/s0735-1097(98)00026-6.
3. Arbustini E, Pasotti M, Pilotto A, Pellegrini C, Grasso M, Previtali S, et al. Desmin Accumulation Restrictive Cardiomyopathy and Atrioventricular Block Associated with Desmin Gene Defects. Eur J Heart Fail. 2006;8(5):477-83. doi: 10.1016/j.ejheart.2005.11.003.
4. Hancock EW. Differential Diagnosis of Restrictive Cardiomyopathy and Constrictive Pericarditis. Heart. 2001;86(3):343-9. doi: 10.1136/heart.86.3.343.
5. Chintanaphol M, Orgil BO, Alberson NR, Towbin JA, Purevjav E. Restrictive Cardiomyopathy: From Genetics and Clinical Overview to Animal Modeling. Rev Cardiovasc Med. 2022;23(3):108. doi: 10.31083/j.rcm2303108.
6. Franz WM, Müller OJ, Katus HA. Cardiomyopathies: From Genetics to the Prospect of Treatment. Lancet. 2001;358(9293):1627-37. doi: 10.1016/S0140-6736(01)06657-0.
7. Goldfarb LG, Park KY, Cervenáková L, Gorokhova S, Lee HS, Vasconcelos O, et al. Missense Mutations in Desmin Associated with Familial Cardiac and Skeletal Myopathy. Nat Genet. 1998;19(4):402-3. doi: 10.1038/1300.
8. Su W, van Wijk SW, Brundel BJJM. Desmin Variants: Trigger for Cardiac Arrhythmias? Front Cell Dev Biol. 2022;10:986718. doi: 10.3389/fcell.2022.986718.
9. Cabral M, Ruivo C, Martins H. Desmin-Related Cardiomyopathy in a Young Woman Presented with an Infra-Hisian Atrioventricular Block. Cardiol Young. 2024;34(12):2688-90. doi: 10.1017/S1047951124036333.
10. Jurcu RO, Bastian AE, Militaru S, Popa A, Manole E, Popescu BA, et al. Discovery of a New Mutation in the Desmin Gene in a Young Patient with Cardiomyopathy and Muscular Weakness. Rom J Morphol Embryol. 2017;58(1):225-30.
11. Olivé M, Goldfarb L, Moreno D, Laforet E, Dagvadorj A, Sambuughin N, et al. Desmin-Related Myopathy: Clinical, Electrophysiological, Radiological, Neuropathological and Genetic Studies. J Neurol Sci. 2004;219(1):125-37. doi: 10.1016/j.jns.2004.01.007.
12. Dalakas MC, Park KY, Semino-Mora C, Lee HS, Sivakumar K, Goldfarb LG. Desmin Myopathy, a Skeletal Myopathy with Cardiomyopathy Caused by Mutations in the Desmin Gene. N Engl J Med. 2000;342(11):770-80. doi: 10.1056/NEJM200003163421104.
13. Silva CP, Bacal F, Benvenuti LA, Bocchi EA. Desmin-Related Restrictive Cardiomyopathy. Arq Bras Cardiol. 2007;89(6):165-8. doi: 10.1590/S0066-782X2007001800014.

This is an open-access article distributed under the terms of the Creative Commons Attribution License