Case Report

[18F]FDG PET/CT in the Investigation of Infective Endocarditis in a Patient with a Prosthetic Aortic Valve: A Case Report

Euclides Antonio Costa,[1] Isabella Bergamini,[1] Walter Meneses Camacho,[1] Bruno Gomes Padilha,[1] Rinaldo Focaccia Siciliano,[1] Maria Clementina Pinto Giorgi,[1] Vitor Emer Egypto Rosa,[1] Flávio Tarasoutchi,[1] Leandro Tinagero Hyppolito,[1] José Soares Junior[1]

Universidade de São Paulo, Instituto do Coração,[1] São Paulo, SP – Brazil

Abstract

Infective endocarditis is a disease involving microbial infection of the endothelial surface of the heart. Diagnosis is currently based on the Duke-ISCVID criteria, published in 2023, which update the modified Duke criteria. The Duke-ISCVID criteria comprise major and minor criteria, which are categorized as microbiologic, laboratory, imaging, and surgical. [18F]fluorodeoxyglucose positron emission tomography/computed tomography ([18F]FDG PET/CT) is one of the major criteria, allowing reclassification of a significant number of suspected prosthetic valve endocarditis cases from "possible" to "definite" infective endocarditis. PET/CT also has the potential to detect clinically relevant extracardiac infectious foci, leading to more appropriate treatment regimens and surgical interventions. We report the case of a patient with a prosthetic valve diagnosed with infective endocarditis with a splenic septic embolus demonstrated by PET/CT.

Introduction

Infective endocarditis is a disease involving microbial infection of the endothelial surface of the heart. It occurs when a pathogen originating in another location in the body travels to the heart via the bloodstream and lodges in cardiac tissues.[1] Valvular infection leads to the formation of vegetations composed of fibrin, platelets, and microorganisms, which can detach from the heart and migrate as emboli to organs such as the kidneys, lungs, skin, spleen, and brain, as well as other central nervous system structures.[2]

The vast majority of infective endocarditis cases result from infection by Gram-positive streptococci, staphylococci, and enterococci. Together, these three groups account for 80% to 90% of all cases, and *Staphylococcus aureus* accounts for approximately 30% of cases in the developed world.[3]

Keywords

Endocarditis; Fluorodeoxyglucose F18; Positron Emission Tomography Computed Tomography; Positron-Emission Tomography.

Mailing Address: Euclides Antonio Costa •
Serviço de Medicina Nuclear e Imagem Molecular. InCor-HCFMUSP. Av. Dr. Enéas Carvalho de Aguiar, 44. Postal code: 05403-900. Cerqueira César, São Paulo, SP – Brazil
E-mail: euclidesdacosta20@yahoo.com
Manuscript received October 31, 2025; revised manuscript July 8, 2026; accepted September 8, 2026.
Editor responsible for the review: Wolney de Andrade Martins

DOI: https://doi.org/10.36660/ijcs.20250253

The epidemiology of infective endocarditis varies, with higher incidence rates observed in patients with risk factors such as pre-existing heart disease, prosthetic heart valves and implantable devices, intravenous illicit drug use, and invasive procedures. It is a rare disease, with an estimated annual incidence of 3 to 10 cases per 100,000 people.[4]

The signs and symptoms of infective endocarditis can vary depending on the severity of the infection. Acute clinical manifestations may include high fever, chills, sweating, chest pain, fatigue, and altered mental status.[5] Extracardiac manifestations may also occur, albeit infrequently, including subcutaneous Osler nodes, signs of cutaneous hemorrhage or Roth spots, Janeway lesions, splenomegaly, and localized peritonitis.[6] The disease has an unfavorable prognosis, with a high 7-year mortality rate of 56%.[7]

Diagnosis of infective endocarditis is challenging, and prosthetic valve endocarditis poses even greater clinical difficulties. The clinical presentation is often atypical, especially in the early postoperative period, when fever and a systemic inflammatory response are common even in the absence of macroscopic prosthetic abnormalities on cardiac imaging.[1] Diagnosis of infective endocarditis is primarily based on the results of echocardiography and blood cultures. However, both are associated with a sensitivity of only 60% for the definitive diagnosis of endocarditis.[8] The modified Duke criteria, updated in 2023, are widely used in clinical practice for this purpose and serve as a tool for decisions related to patient management.[6] The updated criteria, known as the 2023 Duke-ISCVID (International Society for Cardiovascular Infectious Diseases) criteria, consist of major and minor criteria categorized as microbiologic, laboratory, imaging, and surgical.[6] The inclusion of positron emission tomography/computed tomography (PET/CT) as a major criterion for prosthetic valve endocarditis overcomes the diagnostic limitations of echocardiography when evaluating prosthetic material, allowing a large proportion of suspected prosthetic valve endocarditis cases to be reclassified from "possible" to "definite."[9] Early diagnosis is crucial to avoid treatment delays, which are associated with a worse prognosis.[10]

Case report

A 42-year-old male patient with a history of aortic insufficiency, leaflet fibrosis/retraction, and left ventricular remodeling had undergone aortic valve replacement with a size-23 Braile bovine pericardial bioprosthesis 5 years prior. He was admitted with nonspecific malaise, headache, and low-grade fever spikes over the preceding week. Blood cultures revealed growth of *Streptococcus mitis/oralis* and *S. viridans*,

raising suspicion of infective endocarditis. Transthoracic echocardiography showed mitro-aortic thickening, with no vegetations, and coronary CT angiography reported nonspecific diffuse thickening of the mitral valve anterior leaflet, extending to the mitro-aortic interface. Given these nonspecific findings, he was referred to our department for PET/CT.

PET/CT demonstrated focal areas of moderately increased glycolytic metabolism adjacent to the aortic valve prosthesis (SUVmax: 6.0; Figure 1) and a focal area of increased uptake at the inferior splenic margin (SUVmax: 4.2; Figure 2). The findings were thus interpreted as positive for infective endocarditis with probable splenic embolization.

The patient was initially receiving combination antibiotic therapy with ampicillin, oxacillin, and ceftriaxone. Following the blood culture results, treatment was adjusted to ceftriaxone at a dose of 1 g administered twice daily. Subsequently, upon confirmation of infective endocarditis with splenic embolization via PET/CT, the antibiotic regimen was modified to ceftriaxone at a dose of 2 g twice daily. The patient showed a favorable clinical and laboratory response. The general surgery team evaluated the splenic embolization/infarction, and a conservative treatment approach was chosen.

The patient remained asymptomatic from a cardiovascular perspective, with a normally functioning prosthesis, and was prescribed rivaroxaban 20 mg/day for 3 months.

Discussion

According to the modified Duke criteria, which are the foremost diagnostic criteria, definite infective endocarditis is primarily based on positive blood cultures showing typical microorganisms and/or evidence of infective endocarditis on echocardiography.[7] However, despite continuous advances in echocardiographic imaging, especially transthoracic echocardiography, and microbiological techniques, diagnosis of prosthetic valve endocarditis and intracardiac device infections remains challenging; this is largely because echocardiography and blood cultures yield inconclusive results in over 20% of cases, particularly during the early stages of the disease.[7] Findings from various PET/CT studies demonstrated its potential to improve diagnosis of infective

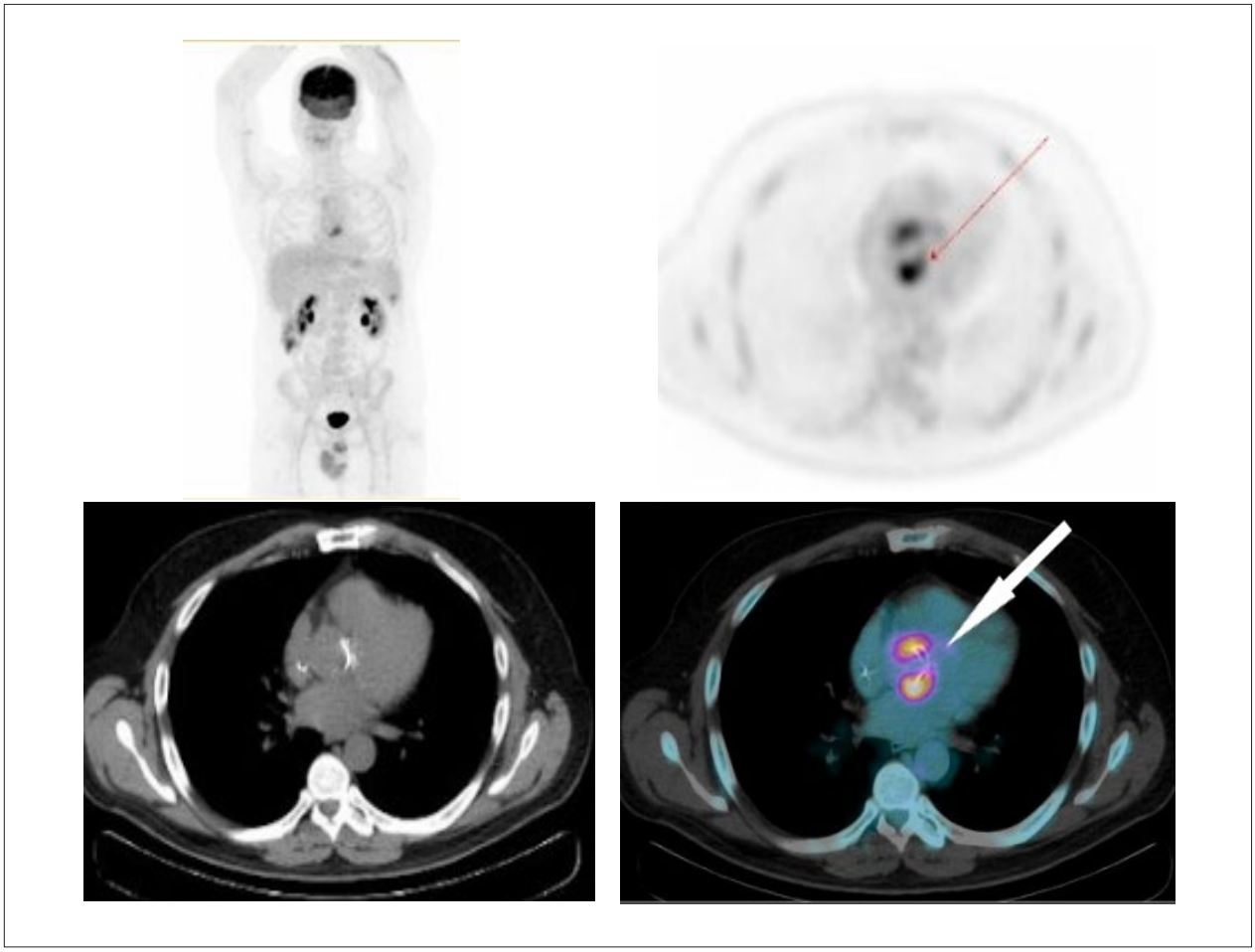

Figure 1 – *PET/CT imaging: maximum intensity projection in the upper left image; remaining images show axial PET slices (upper right), CT (lower left), and PET/CT fusion (lower right), demonstrating focal areas of increased metabolism adjacent to the aortic valve prosthesis (arrows), confirming the diagnosis of local infection.*

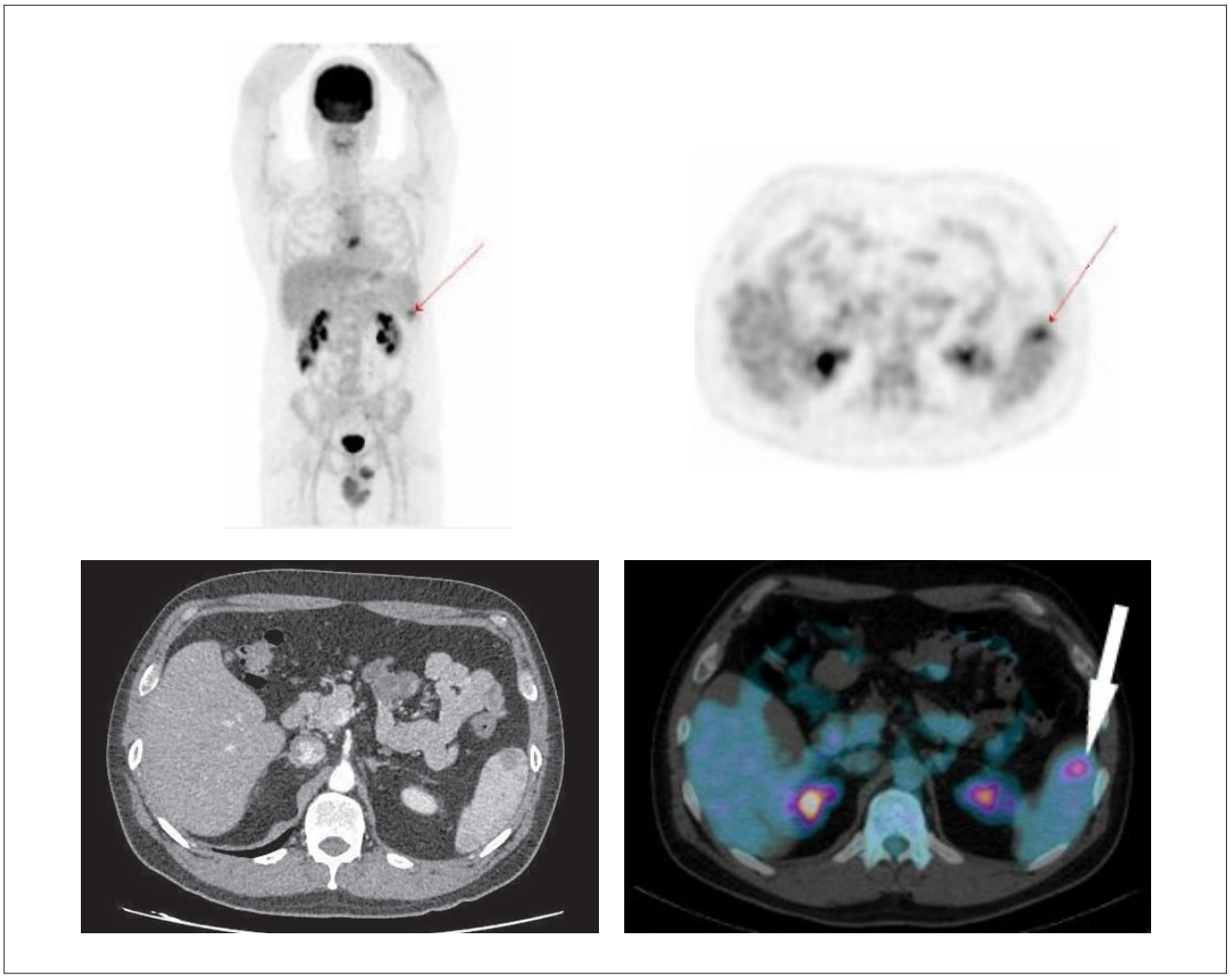

Figure 2 – *PET/CT image showing focal increased uptake at the inferior margin of the spleen, a finding consistent with septic embolism.*

endocarditis if incorporated into the initial assessment,[9-12] thereby enhancing the accuracy of the modified Duke criteria. PET/CT has recently been included in the 2023 Duke-ISCVID criteria as a major imaging criterion.[12] PET/CT overcomes the diagnostic limitations of echocardiography when evaluating prosthetic material, allowing a significant proportion of suspected prosthetic valve endocarditis cases to be reclassified from "possible" to "definite" infective endocarditis.[12] Furthermore, as a whole-body examination, it allows assessment of extracardiac involvement associated with infective endocarditis.

Initially used to detect neoplasms due to the high glucose uptake by cancer cells, PET/CT has come to play a significant role in identifying infectious and inflammatory diseases. This is because immune cells, such as leukocytes and macrophages, increase glucose consumption during inflammatory or infectious processes. The increased demand for glucose is met by the upregulation of glucose transporters (GLUT), resulting in greater FDG uptake in these cells than in normal cells; furthermore, immune-mediated cytokine release also plays a significant role in GLUT upregulation.[8]

Although there is no consensus regarding the standard preparation protocol, suppression of myocardial fluorodeoxyglucose (FDG) uptake is typically achieved through a high-fat, low-carbohydrate diet for 24 hours.[10] The patient in the reported case followed a low-carbohydrate, high-fat diet on the day prior to the examination, followed by a 12-hour fast during which he consumed only pure water. Additionally, the patient was instructed to take 1 omega-3 capsule (1000 mg) 3 times daily with his main meals to increase fat intake.

Following injection of the radiotracer, the patient remained at rest for 60 minutes and consumed 3 glasses of water provided by the facility during this period. Subsequently, dedicated cardiac images were acquired to evaluate foci of radiotracer uptake in the region of the prosthetic valve. Given the ability of PET/CT to detect distant sites of infective endocarditis, whole-body images were also acquired.

The images were interpreted by means of visual and quantitative analyses based on the maximum standardized uptake value (SUVmax). The pattern of FDG uptake at the prosthetic valve ring is crucial for diagnosing infective endocarditis via PET/CT. Intense FDG uptake, focal/multifocal

areas, or heterogeneous areas detected after 3 months constitute a major criterion under the revised Duke criteria; however, uptake observed within a shorter interval is still considered a positive finding, albeit classified as a minor Duke criterion. It is worth noting that the 3-month interval is not a prerequisite for PET imaging, and the uptake pattern is the most important factor.[12] Care must be taken with potential FDG uptake in the myocardium adjacent to the valve and artifacts caused by metallic prosthetic valve components, as well as with false-positive results and technical limitations, such as inflammatory uptake in the early postoperative period or antibiotic use before the examination.[10] In this case report, intense, heterogeneous uptake was observed near the prosthetic aortic valve, confirming the diagnosis of infective endocarditis. Whole-body imaging is particularly important for diagnosing septic embolism, as seen in the present case, where a focal area of hypermetabolism was identified at the inferior splenic margin, confirming an infectious embolic source. The 2023 European Society of Cardiology/European Association of Nuclear Medicine (ESC/EANM) guidelines also recommend whole-body PET/CT imaging for symptomatic patients with native or prosthetic valve endocarditis to detect peripheral lesions.[9]

PET/CT is particularly valuable for diagnosing cardiac infection in patients with complex cardiac implants, such as multiple prosthetic valves, combined valve and aortic tube grafts, and congenital heart disease.[12] Consequently, PET/CT is currently indicated for patients with a high clinical suspicion of prosthetic valve endocarditis and nondiagnostic echocardiography.[12] This was demonstrated in the reported case, in which echocardiography was negative, whereas PET/CT was positive and also detected septic embolism. PET/CT helps rule out infective endocarditis when the result is negative and aids in confirming the diagnosis when clinical suspicion exists but remains undefined by other imaging methods.[6]

Conclusion

PET/CT is a valuable diagnostic tool for evaluating challenging cases of infective endocarditis, especially prosthetic valve endocarditis. Beyond cardiac assessment, PET/CT has the potential to detect clinically relevant extracardiac sites of infection, allowing more appropriate treatment regimens and surgical interventions. In this case, PET/CT confirmed the diagnosis of prosthetic valve endocarditis and detected a splenic septic embolus, leading to an adjustment in antibiotic dosage and a satisfactory clinical outcome.

Author Contributions

Conception and design of the research: Soares Junior J; acquisition of data and writing of the manuscript: Costa EA, Bergamini I, Camacho WM; analysis and interpretation of the data and statistical analysis: Costa EA; critical revision of the manuscript for intellectual content: Costa EA, Padilha BG, Hyppolito LT, Giorgi MCP, Rosa VEE, Siciliano RF, Tarasoutchi F.

Potential Conflict of Interest

No potential conflict of interest relevant to this article was reported.

Sources of Funding

There were no external funding sources for this study.

Study Association

This study is not associated with any thesis or dissertation work.

Ethics Approval and Consent to Participate

This study was approved by the Research Ethics Committee of the Universidade de São Paulo under approval number 5.775.873. All the procedures in this study were in accordance with the 1975 Helsinki Declaration, updated in 2013. Informed consent was obtained from all participants included in the study.

Use of Artificial Intelligence

The authors did not use any artificial intelligence tools in the development of this work.

Availability of Research Data

The underlying content of the research text is contained within the manuscript.

References

1. Carvalho LC, Teixeira FAO, Moraes PHA, Pereira AL, Nogueira THM, Borges JML, et al. Infectious Endocarditis: Na Approach on Microbiological Variance in the Face of Differente Factors. Braz J Health Rev. 2022;5(1):2867-74. doi: 10.34119/bjhrv5n1-254.
2. Khaledi M, Sameni F, Afkhami H, Hemmati J, Dezfuli AAZ, Sanae MJ, et al. Infective Endocarditis by HACEK: A Review. J Cardiothorac Surg. 2022;17(1):185. doi: 10.1186/s13019-022-01932-5.
3. Barnett R. Infective Endocarditis. Lancet. 2016;388(10050):1148. doi: 10.1016/S0140-6736(16)31602-6.
4. Cahill TJ, Prendergast BD. Infective Endocarditis. Lancet. 2016;387(10021):882-93. doi: 10.1016/S0140-6736(15)00067-7.
5. Mesquita CT, Yahiro DS, Silva NS, Ribeiro BFC, Sales J, Laranja MA, et al. Infective Endocarditis: A Narrative Review. Med Ciênc Arte. 2023;2(1):73-84.
6. Yallowitz AW, Nguyen AD. Infective Endocarditis. In: StatPearls [Internet]. Treasure Island: StatPearls Publishing; 2026 [cited 2026 Sep 24]. Available from: https://www.ncbi.nlm.nih.gov/books/NBK557641/.
7. McDonald EG, Aggrey G, Aslan AT, Casias M, Cortes-Penfield N, Dong MQD, et al. Guidelines for Diagnosis and Management of Infective Endocarditis in Adults: A WikiGuidelines Group Consensus Statement. JAMA Netw Open. 2023;6(7):e2326366. doi: 10.1001/jamanetworkopen.2023.26366.

8. Kung BT, Seraj SM, Zadeh MZ, Rojulpote C, Kothekar E, Ayubcha C, et al. An Update on the Role of 18F-FDG-PET/CT in Major Infectious and Inflammatory Diseases. Am J Nucl Med Mol Imaging. 2019;9(6):255-73.

9. Delgado V, Marsan NA, Waha S, Bonaros N, Brida M, Burri H, et al. 2023 ESC Guidelines for the Management of Endocarditis. Eur Heart J. 2023;44(39):3948-4042. doi: 10.1093/eurheartj/ehad193.

10. Grossman GB, Carreira LTF. The Role of PET/CT in the Diagnosis of Infective Endocarditis. Arq Bras Cardiol: Imagem Cardiovasc. 2019;32(3):209-13. doi: 10.5935/2318-8219.20190037.

11. Camargo RA, Bitencourt MS, Meneghetti JC, Soares J, Gonçalves LFT, Buchpiguel CA, et al. The Role of 18F-Fluorodeoxyglucose Positron Emission Tomography/Computed Tomography in the Diagnosis of Left-Sided Endocarditis: Native vs Prosthetic Valves Endocarditis. Clin Infect Dis. 2020;70(4):583-94. doi: 10.1093/cid/ciz267.

12. Fowler VG, Durack DT, Selton-Suty C, Athan E, Bayer AS, Chamis AL, et al. The 2023 Duke-International Society for Cardiovascular Infectious Diseases Criteria for Infective Endocarditis: Updating the Modified Duke Criteria. Clin Infect Dis. 2023;77(4):518-26. doi: 10.1093/cid/ciad271.

This is an open-access article distributed under the terms of the Creative Commons Attribution License