Persistent Spontaneous Coronary Artery Dissection with Refractory Angina: Ischemia and Intravascular Ultrasound-Guided Revascularization

Kelvyn Vital,[1] Maria Isabel Sousa Vidal,[1] Milena Montans Jordão,[1] Pietra Moreira Vieira,[1] Maíra Kuster Machado,[1] Pedro Henrique de Morais Luvizotto,[1] Elry Medeiros Vieira Segundo Neto,[1] Louis Nakayama Ohe,[1] Ricardo Pavanello,[1] Fausto Feres[1]

Instituto Dante Pazzanese de Cardiologia,[1] São Paulo, SP – Brazil

Introduction

Spontaneous coronary artery dissection (SCAD) is a non-atherosclerotic and underdiagnosed cause of acute coronary syndrome (ACS), particularly in women, estimated to account for 1–4% of all ACS episodes and a considerably higher proportion among young women with ACS.[1-3] It is characterized by a sudden dissection of the coronary arterial wall towards the media, resulting in the formation of an intramural hematoma and compression of the true lumen, which can lead to ischemia or myocardial infarction.[2]

The pathophysiology of SCAD differs fundamentally from that of atherosclerotic coronary artery disease, with proposed mechanisms including intimal rupture ("inside-out") and primary intramural hemorrhage from the vasa vasorum ("outside-in").[2,3] These processes contribute to diverse angiographic presentations and can make diagnosis and management challenging.

Current guidelines and position papers recommend conservative management in hemodynamically stable patients with preserved coronary flow. This approach is supported by the high rates of spontaneous healing and the greater technical complexity and risk of complications associated with percutaneous coronary intervention (PCI) in this context.[2,4,5] Retrospective analyses have shown that, in most patients, angiographic healing occurs without intervention, supporting an initial conservative approach.[5,6]

Nevertheless, SCAD is a dynamic condition, and some patients develop persistent or recurrent symptoms accompanied by evidence of myocardial ischemia. In these cases, revascularization may be necessary, although the ideal timing and selection criteria remain poorly defined in the absence of randomized data.[4,5]

Keywords

Coronary Vessels; Interventional Ultrasonography; Percutaneous Coronary Intervention; Myocardial Ischemia; Acute Coronary Syndrome

Mailng Address: Kelvyn Vital •
Instituto Dante Pazzanese de Cardiologia – Av. Dante Pazzanese, 500. Postal Code 04012-909, São Paulo, SP – Brazil
E-mail: kelvynvital@gmail.com
Mansucript received June 10, 2026, revised manuscript August 13, 2026, accepted September 02, 2026
Editor responsible for the review: Henrique Ribeiro

DOI: https://doi.org/10.36660/abc.20260469i

We report a case of conservatively managed SCAD that progressed with persistent symptoms and documented ischemia, requiring intravascular ultrasound-guided PCI, highlighting the importance of structured follow-up and individualized management.

Case presentation

A 46-year-old woman with a history of smoking (60 pack-years) and obesity presented in February 2021 with typical acute-onset chest pain consistent with unstable angina, described as retrosternal pressure radiating to the left upper limb and associated with sweating. The patient had no other known cardiovascular comorbidities but had a family history of coronary artery disease (mother with myocardial infarction at age 61). She was not regularly using any medication before the event. She was postmenopausal and was not receiving hormone therapy. Her body mass index was 37.47 kg/m^2. She had no known clinical history of systemic inflammatory disease or connective tissue disease. At the time, no systematic investigation of extracoronary arteriopathies, including fibromuscular dysplasia, was performed, although its association with SCAD has been consistently demonstrated in contemporary cohorts.[7] The initial evaluation, including coronary angiography, was performed at another institution, where spontaneous coronary artery dissection affecting the mid-segment of the left anterior descending artery (LAD) was diagnosed. Angiography demonstrated an angiographically evident dissection line, compatible with type 1 SCAD according to the Saw classification, involving the mid-segment of the LAD (Figure 1), with preserved distal flow (TIMI 3). Detailed information on the initial electrocardiographic findings, cardiac biomarkers, and acute phase management was unavailable, as the patient was managed at an external institution.

Due to hemodynamic stability and preserved coronary flow, a conservative management strategy was adopted at that time, in accordance with contemporary recommendations for SCAD. The patient was treated with acetylsalicylic acid, carvedilol, simvastatin, and sublingual nitrates as needed to relieve symptoms. Despite conservative therapy, she developed progressive angina over the following months, accompanied by dyspnea on minimal exertion and reduced functional capacity (New York Heart Association functional class II–III).

In the initial assessment at our service, the patient reported burning chest pain radiating to the upper limbs and worsening

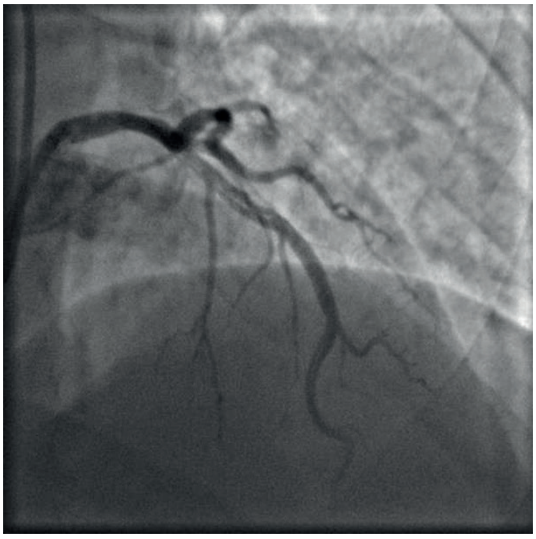

Figure 1 – *Coronary angiography demonstrating spontaneous dissection of the left anterior descending artery, with an angiographically evident dissection line, consistent with type 1 SCAD according to the Saw classification.*

with exertion, which had started approximately eight months prior, associated with dyspnea on exertion, then classified as functional class II. At that time, laboratory tests showed hemoglobin of 13.0 g/dL, creatinine of 0.86 mg/dL, blood glucose of 100 mg/dL, HbA1c of 5.8%, total cholesterol of 133 mg/dL, LDL-c of 53 mg/dL, HDL-c of 36 mg/dL, triglycerides of 221 mg/dL, free T4 of 1.06 ng/dL, TSH of 2.47 μUI/mL, and NT-proBNP of 96 pg/mL, without other clinically relevant laboratory abnormalities. The 12-lead electrocardiogram showed sinus rhythm, without inactive areas or other signs of current or previous ischemia. Blood pressure was 136/84 mmHg, and heart rate was 74 bpm. The patient was taking carvedilol 6.25 mg twice daily, and the medication regimen was optimized by increasing the carvedilol dose to 12.5 mg twice daily and introducing enalapril 5 mg twice daily.

Despite therapeutic optimization, in the subsequent evaluation the patient remained symptomatic, with functional worsening, presenting angina on minimal exertion, classified as CCS III, including during routine activities such as washing dishes, in addition to dyspnea functional class III, reported even during bathing. At that time, she was using carvedilol 12.5 mg twice daily and enalapril 5 mg twice daily, with blood pressure of 118/72 mmHg and heart rate of 58 bpm. The persistence of limiting symptoms despite the adjustment of drug therapy, already accompanied by a reduction in heart rate and blood pressure, motivated further investigation for objective documentation of myocardial ischemia. Myocardial perfusion scintigraphy with dipyridamole stress demonstrated a perfusion defect involving 16% of the myocardium, of which 6% corresponded to reversible ischemia affecting the anterior apical and septal apical segments, compatible with the territory of the LAD (Figure 2). This approach was chosen to confirm that SCAD was responsible for the patient's symptoms and objective ischemia, avoiding invasive physiological assessment (e.g., fractional flow reserve or resting indices) due to the potential risk of catheter manipulation worsening the dissection.

Given the refractory symptoms and objective evidence of myocardial ischemia, it was decided to proceed with invasive evaluation and possible revascularization. Coronary angiography was performed via right radial access and confirmed the persistence of the lesion in the LAD, with characteristics compatible with SCAD and without evidence of atherosclerotic disease. PCI was performed under intravascular ultrasound (IVUS) guidance (OptiCross 3.0/4.0 MHz) to increase the safety of the procedure and ensure accurate identification of the true lumen. The lesion was successfully transposed with a conventional guidewire (workhorse). IVUS demonstrated a double lumen starting in the proximal segment of the LAD, almost to its ostium, sparing it until the mid-segment, consistent with an intramural hematoma causing compression of the true lumen (Figures 3 and 4). A 3.5 × 38 mm everolimus-releasing drug-eluting stent (Xience Alpine) was successfully implanted from the ostium to the mid-segment of the LAD (Figures 5 and 6). Final IVUS assessment confirmed adequate stent expansion and apposition, with no residual dissection or procedural complications. Final angiography demonstrated restoration of luminal integrity, with TIMI 3 flow.

The patient recovered uneventfully, with complete resolution of angina, and was discharged on optimized drug therapy, including acetylsalicylic acid, clopidogrel, atorvastatin, carvedilol, and enalapril, with dual antiplatelet therapy for 12 months, followed by acetylsalicylic acid indefinitely. She remained asymptomatic throughout the follow-up in 2022. The transthoracic echocardiogram performed in 2023 demonstrated preserved left ventricular ejection fraction (LVEF 63%), without significant structural abnormalities. In 2025, the patient reported dyspnea and retrosternal burning discomfort, without typical anginal features. Repeat myocardial perfusion scintigraphy did not show ischemia, consistent with preserved stent patency. Due to continued smoking, she was referred for pulmonary evaluation and to a structured smoking cessation program.

Discussion

Spontaneous coronary artery dissection is a distinct clinical entity within the spectrum of acute coronary syndromes, characterized by particular pathophysiological mechanisms and management strategies. Unlike atherosclerotic disease, SCAD is defined by the formation of an intramural hematoma that leads to compression of the true lumen and varying degrees of myocardial ischemia.[2,3] Available data support an initial conservative approach in hemodynamically stable patients, since up to 70–97% of affected vessels exhibit spontaneous healing.[2,5]

Large contemporary registries have characterized SCAD as a condition that predominantly affects middle-aged women, frequently in the absence of traditional atherosclerotic risk factors and with a significant association with extracoronary



Figure 2 – *Myocardial perfusion scintigraphy demonstrating reversible ischemia in the anterior apical and apical septal segments, consistent with the territory of the left anterior descending artery (LAD). The perfusion defect involved 16% of the myocardium, of which 6% corresponded to reversible ischemia.*

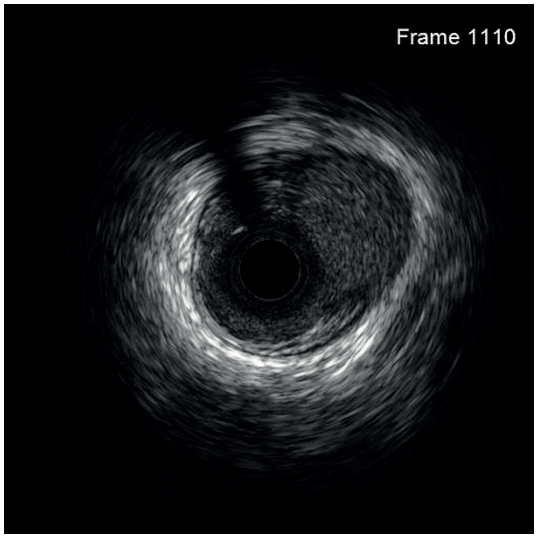

Figure 3 – *Intravascular ultrasound demonstrating the distal portion of the dissection of the anterior descending artery. A double lumen is evident with an intramural hematoma compressing the true lumen.*



Figure 4 – *Intravascular ultrasound demonstrating the proximal portion of the anterior descending artery with intramural hematoma. The true lumen is compressed by the dissection, confirming the proximal extension of the SCAD.*

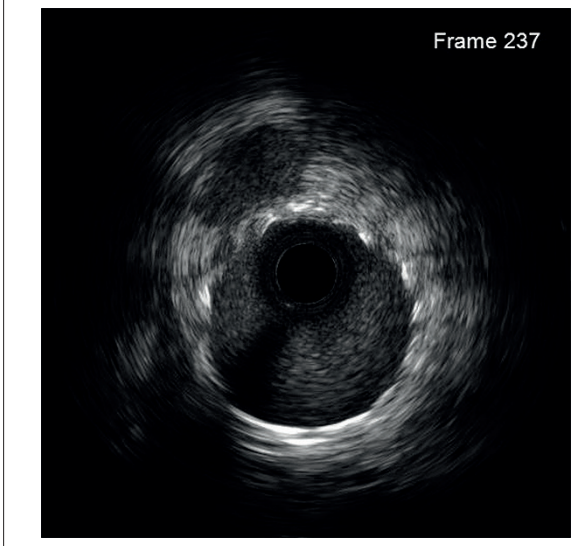

Figure 5 – *A drug-eluting everolimus-releasing stent was positioned and implanted in the distal portion of the dissection lesion, guided by intravascular ultrasound. Intravascular ultrasound confirmed adequate stent expansion and apposition.*

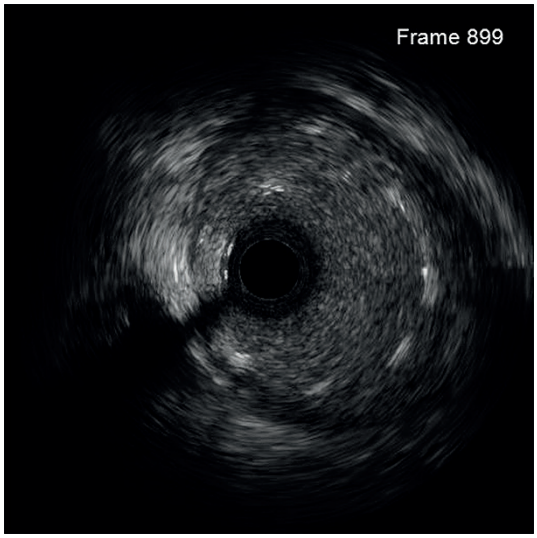

Figure 6 – *SA drug-eluting stent containing everolimus was positioned and implanted in the proximal portion of the dissection lesion, guided by intravascular ultrasound. The final intravascular ultrasound image demonstrates complete coverage of the dissection and restoration of normal vascular architecture.*

arteriopathies, particularly fibromuscular dysplasia.[9-12] A Canadian cohort study, with three years of follow-up, documented a low rate of de novo SCAD recurrence (2.4%) and mortality (0.8%), identifying extracoronary fibromuscular dysplasia, genetic disorders, and peripartum SCAD as independent predictors of major long-term adverse events.[9] Similar data were reported by the Spanish multicenter registry, which described a predominance of postmenopausal women and preferential involvement of the left anterior descending artery.[10] In Brazil, data from the SCALIBUR registry, including 230 patients with SCAD, contributed to the contemporary characterization of the clinical and angiographic characteristics of the disease in the Brazilian population, consistent with what was observed in international cohorts.[11] Similar findings regarding the prognostic impact of SCAD in young women were described in a Japanese multicenter cohort.[12]

Furthermore, PCI in SCAD is technically challenging due to difficulties in advancing the guidewire through the true lumen, the risk of dissection propagation, and lower success rates compared to atherosclerotic lesions.[5,6] However, a clinically relevant subgroup of patients may develop persistent or recurrent symptoms. In this context, it is crucial to distinguish benign residual chest pain, commonly reported in SCAD, from true myocardial ischemia. Functional tests, particularly myocardial perfusion scintigraphy, play an important role in providing an objective assessment of the ischemic burden and guiding therapeutic decision-making.[13]

In this case, the reversible ischemic burden was relatively low (6%), not constituting, in isolation, an indication for revascularization. However, its presence provided objective evidence of ischemia in the LAD territory in a patient with persistent and limiting symptoms despite drug treatment, associated with angiographic persistence of SCAD months after the initial event. Thus, the decision for revascularization resulted from the integration of clinical evolution, objective demonstration of ischemia, and coronary anatomy, and not from an isolated ischemic burden threshold. Non-invasive ischemia testing was chosen over invasive physiological assessment to minimize the risk of iatrogenic extension of the dissection, given the fragility of the vascular wall in the LAD. This individualized decision is aligned with contemporary coronary revascularization guidelines, which recognize the limitation of specific randomized evidence for ACS and recommend that the indication for revascularization in this context be based on individualized clinical judgment, the persistence of symptoms, and objective evidence of ischemia, and not on isolated anatomical criteria.[14] Intracoronary imaging has emerged as a fundamental tool for both the diagnosis and interventional management of SCAD.

Techniques such as IVUS and optical coherence tomography (OCT) allow for detailed characterization of the arterial wall, including identification of the true lumen, assessment of intramural hematoma, and optimization of stent expansion.[15-17] Contemporary reviews reinforce that confirmation of the guidewire position in the true lumen under intracoronary imaging guidance can help minimize the risk of iatrogenic dissection propagation during PCI in SCAD.[18] In cases where PCI is necessary, intracoronary imaging can assist in confirming the guidewire position in the true lumen, characterizing the extent of the intramural hematoma, and optimizing stent implantation. In the present case, IVUS was

particularly useful in confirming the true lumen and guiding the revascularization strategy.

Traditional cardiovascular risk factors, including smoking and obesity, were also present. Although SCAD typically affects individuals with limited atherosclerotic burden, growing evidence suggests a clinical and pathophysiological overlap between atherosclerosis and SCAD in some patients.[2,19] In this context, the primary goal of PCI was symptom control and recovery of functional capacity, not the reduction of major cardiovascular events. There is no established evidence that revascularization of stable patients with SCAD reduces mortality or myocardial infarction recurrence, and the interventional decision should be individualized. Contemporary reviews corroborate the absence of robust data supporting a mortality benefit with revascularization in stable patients with SCAD, reinforcing the need for therapeutic individualization.[20]

The favorable long-term outcome observed in this case reinforces the importance of structured follow-up in patients with SCAD. Given the variable clinical course, continuous clinical surveillance and, in selected patients with persistent or recurrent symptoms, functional assessment can help identify those who may eventually require late revascularization.

This case illustrates that, although conservative therapy remains the standard treatment, an individualized approach based on clinical evolution and objective evidence of ischemia can provide favorable outcomes.

Conclusions

This case illustrates the potential role of intracoronary imaging-guided PCI in carefully selected patients with persistent SCAD, refractory symptoms, and objective evidence of ischemia. Although conservative management remains the preferred strategy for most stable patients, integrating clinical course, functional assessment, and intracoronary imaging can aid decision-making when revascularization becomes necessary.

Author Contributions

Conception and design of the research: Vital K, Segundo Neto EMV, Ohe LN, Pavanello R, Feres F; Data collection, Data analysis and interpretation and Manuscript drafting: Vital K, Vidal MIS, Jordão MM, Vieira PM, Machado MK, Luvizotto PHM; Critical revision of the manuscript for important intellectual content: Segundo Neto EMV, Ohe LN, Pavanello R, Feres F.

Potential conflict of interest

No potential conflict of interest relevant to this article was reported.

Sources of funding

There were no external funding sources for this study.

Study association

This study is not associated with any thesis or dissertation work.

Ethics approval and consent to participate

This study was approved by the Ethics Committee of the Instituto Dante Pazzanese de Cardiologia under the protocol number 7.904.853. All the procedures in this study were in accordance with the 1975 Helsinki Declaration, updated in 2013.

Use of Artificial Intelligence

The authors did not use any artificial intelligence tools in the development of this work.

Data Availability Statement

The underlying content of the research text is contained within the manuscript.

References

1. Tweet MS, Hayes SN, Pitta SR, Simari RD, Lerman A, Lennon RJ, et al. Clinical Features, Management, and Prognosis of Spontaneous Coronary Artery Dissection. Circulation. 2012;126(5):579-88. doi: 10.1161/CIRCULATIONAHA.112.105718.
2. Hayes SN, Kim ESH, Saw J, Adlam D, Arslanian-Engoren C, Economy KE, et al. Spontaneous Coronary Artery Dissection: Current State of the Science: A Scientific Statement from the American Heart Association. Circulation. 2018;137(19):e523-57. doi: 10.1161/CIR.0000000000000564.
3. Saw J, Aymong E, Sedlak T, Buller CE, Starovoytov A, Ricci D, et al. Spontaneous Coronary Artery Dissection: Association with Predisposing Arteriopathies and Precipitating Stressors and Cardiovascular Outcomes. Circ Cardiovasc Interv. 2014;7(5):645-55. doi: 10.1161/CIRCINTERVENTIONS.114.001760.
4. Byrne RA, Rossello X, Coughlan JJ, Barbato E, Berry C, Chieffo A, et al. 2023 ESC Guidelines for the Management of Acute Coronary Syndromes. Eur Heart J. 2023;44(38):3720-826. doi: 10.1093/eurheartj/ehad191.
5. Tweet MS, Eleid MF, Best PJ, Lennon RJ, Lerman A, Rihal CS, et al. Spontaneous Coronary Artery Dissection: Revascularization versus Conservative Therapy. Circ Cardiovasc Interv. 2014;7(6):777-86. doi: 10.1161/CIRCINTERVENTIONS.114.001659.
6. Alfonso F, Paulo M, Lennie V, Dutary J, Bernardo E, Jiménez-Quevedo P, et al. Spontaneous Coronary Artery Dissection: Long-Term Follow-Up of a Large Series of Patients Prospectively Managed with a "Conservative" Therapeutic Strategy. JACC Cardiovasc Interv. 2012;5(10):1062-70. doi: 10.1016/j.jcin.2012.06.014.
7. Petropoulos T, Shah A, Dueck A, Hawkes C, Tobe SW, Kingston W, et al. Fibromuscular Dysplasia: A Focused Review for the Cardiologist. CJC Open. 2024;6(11):1274-88. doi: 10.1016/j.cjco.2024.07.014.
8. Saw J. Coronary Angiogram Classification of Spontaneous Coronary Artery Dissection. Catheter Cardiovasc Interv. 2014;84(7):1115-22. doi: 10.1002/ccd.25293.
9. Saw J, Starovoytov A, Aymong E, Inohara T, Alfadhel M, McAlister C, et al. Canadian Spontaneous Coronary Artery Dissection Cohort Study: 3-Year Outcomes. J Am Coll Cardiol. 2022;80(17):1585-97. doi: 10.1016/j.jacc.2022.08.759.

10. García-Guimaraes M, Bastante T, Macaya F, Roura G, Sanz R, Alvarado JCB, et al. Spontaneous Coronary Artery Dissection in Spain: Clinical and Angiographic Characteristics, Management, and in-Hospital Events. Rev Esp Cardiol. 2021;74(1):15-23. doi: 10.1016/j.rec.2020.04.002.

11. Caixeta A, Palmerston V, Teixeira PS, Devito F, Oliveira A, Maia J, et al. TCT-663 Spontaneous Coronary Artery Dissection: Analysis of 230 Patients from the Brazilian SCALIBUR Registry. JACC. 2024;84(18_Suppl):B254-5. doi: 10.1016/j.jacc.2024.09.788.

12. Nakashima T, Noguchi T, Haruta S, Yamamoto Y, Oshima S, Nakao K, et al. Prognostic Impact of Spontaneous Coronary Artery Dissection in Young Female Patients with Acute Myocardial Infarction: A Report from the Angina Pectoris-Myocardial Infarction Multicenter Investigators in Japan. Int J Cardiol. 2016;207:341-8. doi: 10.1016/j.ijcard.2016.01.188.

13. Adlam D, Alfonso F, Maas A, Vrints C; Writing Committee. European Society of Cardiology, Acute Cardiovascular Care Association, SCAD Study Group: A Position Paper on Spontaneous Coronary Artery Dissection. Eur Heart J. 2018;39(36):3353-68. doi: 10.1093/eurheartj/ehy080.

14. Lawton JS, Tamis-Holland JE, Bangalore S, Bates ER, Beckie TM, Bischoff JM, et al. 2021 ACC/AHA/SCAI Guideline for Coronary Artery Revascularization: A Report of the American College of Cardiology/American Heart Association Joint Committee on Clinical Practice Guidelines. J Am Coll Cardiol. 2022;79(2):e21-e129. doi: 10.1016/j.jacc.2021.09.006.

15. Jackson R, Al-Hussaini A, Joseph S, van Soest G, Wood A, Macaya F, et al. Spontaneous Coronary Artery Dissection: Pathophysiological Insights from Optical Coherence Tomography. JACC Cardiovasc Imaging. 2019;12(12):2475-88. doi: 10.1016/j.jcmg.2019.01.015.

16. Mehmedbegović Z, Ivanov I, Čanković M, Perišić Z, Kostić T, Maričić B, et al. Invasive Imaging Modalities in a Spontaneous Coronary Artery Dissection: When "Believing is Seeing". Front Cardiovasc Med. 2023;10:1270259. doi: 10.3389/fcvm.2023.1270259.

17. Hayes SN, Tweet MS, Adlam D, Kim ESH, Gulati R, Price JE, et al. Spontaneous Coronary Artery Dissection: JACC State-of-the-Art Review. J Am Coll Cardiol. 2020;76(8):961-84. doi: 10.1016/j.jacc.2020.05.084.

18. Yang C, Chai J, Saw J. Contemporary Diagnosis and Management of Spontaneous Coronary Artery Dissection. Heart. 2025;111(24):1184-90. doi: 10.1136/heartjnl-2024-324732.

19. Kim ESH. Spontaneous Coronary-Artery Dissection. N Engl J Med. 2020;383(24):2358-70. doi: 10.1056/NEJMra2001524.

20. Offen S, Yang C, Saw J. Spontaneous Coronary Artery Dissection (SCAD): A Contemporary Review. Clin Cardiol. 2024;47(6):e24236. doi: 10.1002/clc.24236.

This is an open-access article distributed under the terms of the Creative Commons Attribution License