Severe Neonatal Cyanosis due to Cor Triatriatum Dexter: A Diagnostic Challenge

Thays Illane Ledo Faria,[1] *Fernando Tadeu Amaral,*[2] *Ricardo Nilsson Sgarbieri,*[1] *Paulo Henrique Manso*[2]

Hospital das Clínicas da Faculdade de Medicina de Ribeirão Preto da Universidade de São Paulo,[1] *SP – Brazil*

Universidade de São Paulo Faculdade de Medicina de Ribeirão Preto,[2] *Ribeirão Preto, SP – Brazil*

Introduction

Cyanotic congenital heart diseases cause morbidity and mortality in the neonatal period. Although echocardiography plays a central role in diagnosing these diseases, rare anomalies may present with nonspecific findings, hindering early recognition and delaying appropriate treatment.

Cor Triatriatum Dexter (CTD), a rare cyanotic congenital heart defect, results from a persistent right valve of the sinus venosus and leads to formation of an anomalous membrane within the right atrium.[1]

We report the case of an infant who presented with severe cyanosis since birth, which was initially attributed to right ventricular hypoplasia. CTD diagnosis was missed by both echocardiogram and catheterization, but this defect was clinically suspected and later confirmed after contrast echocardiography with agitated saline. The patient underwent surgical correction of the defect. This case illustrates that CTD poses diagnostic challenges.

This study was approved by the Research Ethics Committee of the Hospital das Clínicas da Faculdade de Medicina de Ribeirão Preto da Universidade de São Paulo (HCFMRP-USP): 95110926.9.0000.5440.

Case Report

A male infant was born at term via vaginal delivery, without prenatal complications. He had no relevant family history of congenital heart disease.

He was orotracheally intubated in the delivery room due to severe hypoxemia that did not respond to supplemental oxygen. His peripheral oxygen saturation ranged between 55% and 75%. He was admitted to the neonatal intensive care unit, where he remained on invasive mechanical ventilation for 30 days.

During the neonatal hospitalization, the etiology of persistent hypoxemia was extensively investigated. The initial echocardiogram demonstrated moderate right ventricular hypoplasia, a 3.4-mm ostium secundum atrial septal defect, enlarged left cardiac chambers, and mild mitral regurgitation.

During this period, the patient developed ventilator-associated pneumonia, which was clinically treated and resolved. After being extubated, he still depended on low-flow oxygen therapy, with saturations around 70%. Initially, he remained clinically stable and adequately tolerated feeding.

However, over the following weeks, hypoxemia worsened progressively, and desaturation episodes recurred. The previously described echocardiographic findings did not suffice to explain his severe clinical condition. Therefore, he was referred to our tertiary hospital because a cyanotic syndrome of unclear etiology was suspected.

He was transferred to the tertiary center when he was aged 2 months and 17 days and weighed 4.2 kg. Upon admission, he was in good general condition and hemodynamically stable. Nevertheless, he was cyanotic, and his peripheral oxygen saturation lay between 65% and 75% despite supplemental oxygen. He did not present with clinical signs of congestive heart failure or respiratory distress at rest. He was receiving captopril (1.5 mg/kg/day), furosemide (2 mg/kg/day), and spironolactone (1 mg/kg/day).

Cardiovascular examination revealed regular two-beat rhythm, soft second heart sound, and mild systolic murmur at the upper left sternal border. The remaining systems were unremarkable. The medications were discontinued, and the patient remained under close clinical observation. Chest radiography was nonspecific, and the admission electrocardiogram showed low right atrial rhythm and signs of left ventricular hypertrophy (Figure 1).

A repeat echocardiogram performed after admission demonstrated a mildly hypoplastic right ventricle, dilated left cardiac chambers, and a patent foramen ovale with left-to-right shunt (Figure 2).

Propranolol was initiated at 2 mg/kg/day and was administered every 12 hours to control the heart rate and to optimize the pulmonary blood flow. He also received furosemide at 1 mg/kg/day every 12 hours to manage volume.

Despite clinical follow-up and medical management, on his second day of admission, he went into septic shock, and his clinical condition deteriorated: he presented with hemodynamic decompensation, severe hypoxemia refractory to supportive measures, combined metabolic and respiratory acidosis, elevated serum lactate, and signs of circulatory shock. He was admitted to the pediatric intensive care unit and orotracheally intubated, and he required volume expansion and empirical antibiotic therapy.

Keywords

Cyanosis; Congenital Heart Defects; Newborn Infant; Echocardiography

Mailing Address: Paulo Henrique Manso •
Universidade de São Paulo Faculdade de Medicina de Ribeirão Preto - Av. dos Bandeirantes, 3900. Postal Code 14040-900, Ribeirão Preto, SP – Brazil
E-mail: phmanso@fmrp.usp.br
Manuscript received March 20, 2026, revised manuscript March 25, 2026, accepted September 16, 2026
Editor responsible for the review: Vitor Guerra

DOI: https://doi.org/10.36660/abc.20260255i

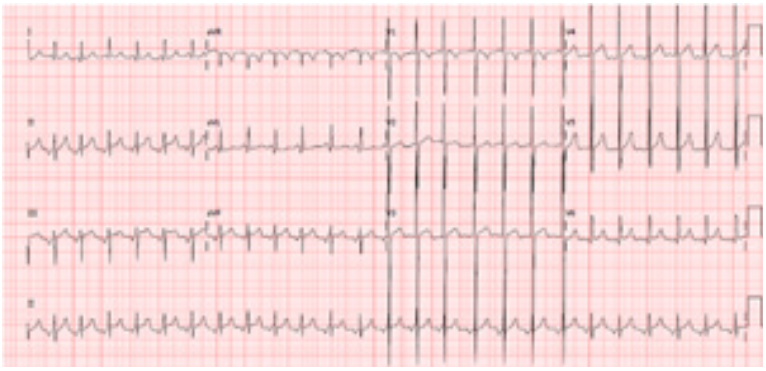

Figure 1 – *Electrocardiogram showing ectopic atrial rhythm and left ventricular hypertrophy.*

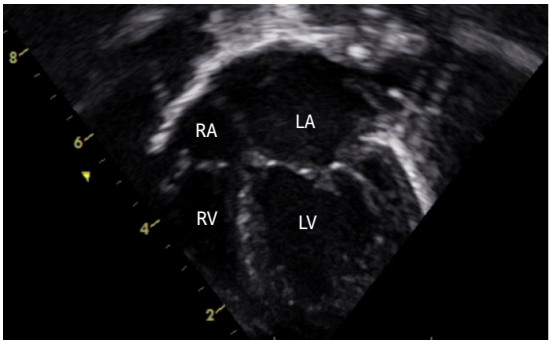

Figure 2 – *Echocardiogram four-chamber view, showing mild hypoplasia of the right chambers. LA: left atrium; LV: left ventricle; RA: right atrium; RV: right ventricle.*

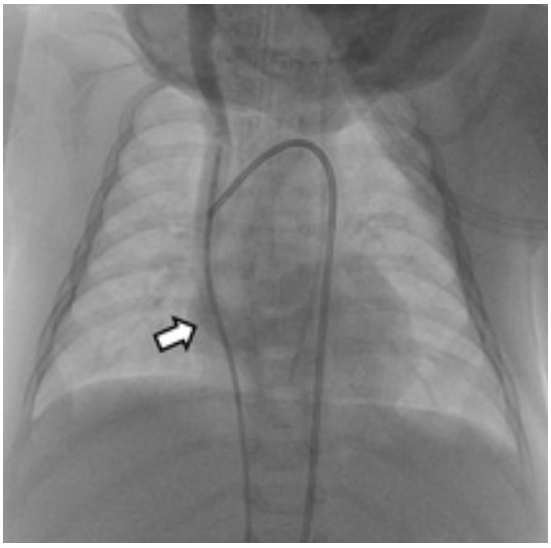

Figure 3 – *Catheterization with injection into the superior vena cava (SVC), with some contrast arriving into the right atrium (RA) - arrow.*

Two additional echocardiograms were performed, but they did not provide new findings. Given that cyanosis persisted, and that anatomical diagnosis was not definitive, diagnostic cardiac catheterization was performed five days after admission. The procedure confirmed an atrial septal defect, but it did not raise suspicion of CTD because the catheter went smoothly from the inferior vena cava to the superior vena cava, even though contrast injected into the superior vena cava was not entirely directed toward the right ventricle (Figure 3).

Due to circulatory dysfunction associated with complex structural congenital heart disease and concomitant infection during the intensive care course, he required hemodynamic support with inotropic agents, including milrinone and epinephrine. He experienced two reversed episodes of cardiac arrest, which lasted approximately two minutes each. Spontaneous circulation returned after resuscitative maneuvers.

Because the persistence of severe cyanosis and the imaging findings were disproportionate, CTD was clinically suspected. Contrast echocardiography with agitated saline, performed on admission day 14, demonstrated that the contrast almost completely passed into the left-sided chambers (Figure 4). Therefore, CTD diagnosis was suggested, and surgical intervention was indicated even though definitive imaging confirmation was absent.

Three days after the contrast echo, when the patient was aged 3 months and 4 days, he underwent open-heart surgical repair via median sternotomy. Intraoperatively, an anomalous membrane of the atrial septum consistent with CTD was identified. The interatrial septum was completely resected, which converted the atria into a single chamber. The septum was then reconstructed with bovine pericardium, which appropriately redirected systemic and pulmonary venous return.

The patient evolved with satisfactory hemodynamic stability in the postoperative period and was discharged from the intensive care unit nine days after the surgery. During hospitalization in the pediatric cardiology ward, his clinical progression was favorable, so he was sent home after one week, and he was followed up on a specialized outpatient basis.

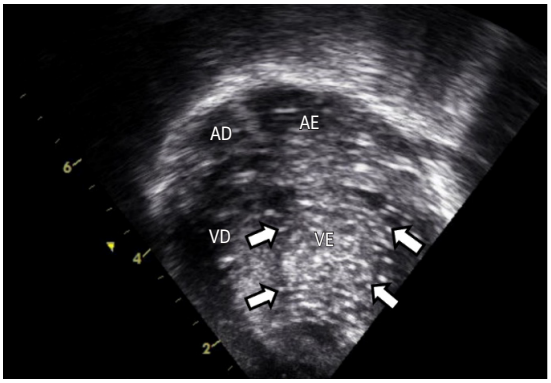

Figure 4 – *Echocardiogram four-chamber view with agitaded saline, highlighting contrast in the left chambers (arrows). LA: left atrium; LV: left ventricle; RA: right atrium; RV: right ventricle.*

At 18 months of follow-up, he remains clinically stable, with no cardiac medications. Ectopic atrial rhythm persists.

Discussion

CTD, a rare congenital malformation, has an estimated incidence of less than 0.025% of all congenital heart diseases.[2] It is characterized by a persistent right valve of the sinus venosus and results in an anomalous membrane that partitions the right atrium. Clinically, CTD patients most commonly present with central cyanosis associated with dyspnea. These symptoms result from systemic venous blood preferentially shunting to the left atrium through a patent foramen ovale, which causes oxygenated and deoxygenated blood to be inadequately mixed.[3]

Clinical expression of this condition varies and depends on anatomical and functional factors, including membrane configuration, associated right-sided malformations, and degree of tricuspid valve involvement. Intracardiac flow may be altered due to partial obstruction within the right atrium or tricuspid valve dysfunction resulting from mechanical interference by the membrane. In certain situations, inferior vena cava return may also be restricted, particularly when the foramen ovale is restrictive, which worsens clinical severity. Neonatal presentation is usually associated with severely obstructed flow to pulmonary circulation.[4]

Echocardiography is the primary initial diagnostic modality and allows a membrane dividing the right atrium to be identified and the hemodynamic impact of this membrane to be assessed. However, visualizing this membrane may be challenging when it is thin, mobile, or unfavorably oriented relative to the ultrasound beam. In neonates with persistent cyanosis, echocardiographic findings may be nonspecific or attributed to more common congenital heart defects, which delays recognition of this rare defect.[5]

Although our patient underwent multiple echocardiographic examinations at both the referring institution and our center, as well as cardiac catheterization, CDT diagnosis was not considered. Mild right-sided chamber hypoplasia and a patent foramen ovale may have contributed to attributing the clinical findings to an alternative etiology, thereby delaying the correct diagnosis. However, mild right-sided hypoplasia would not suffice to explain the severe, persistent hypoxemia that did not respond to ventilatory support and pulmonary vasodilators.

Only after we considered the nonspecific echocardiographic findings, the fact that contrast injection into the superior vena cava did not opacify the pulmonary circulation, and the cyanosis severity, did we suspect CTD. Contrast echocardiography with agitated saline confirmed right-to-left shunting at the atrial level, which supported CTD diagnosis.[6] The patient was referred for surgery without the anatomical defect being definitively confirmed by imaging.

In an era when medical professionals increasingly rely on confirmatory imaging, this case reinforces that clinical reasoning must never be relegated to a secondary role.[7]

The patient presented with ectopic atrial rhythm on admission, which persisted after surgical correction. Given that no literature reports have associated disturbed rhythm with this condition, it is unclear whether this finding is related to the primary defect or merely coincidental.

This case illustrates the complexity of diagnosing CTD, a rare heart defect, in an infant with persistent severe hypoxemia. Diagnosing CTD was difficult because the initial imaging findings did not fully account for the clinical severity. Only after careful clinical reasoning was used, pathophysiology was understood, and complementary examinations were critically appraised did the patient undergo surgical exploration, which ultimately confirmed the CTD diagnosis.

In conclusion, CTD should always be considered in neonates with persistent cyanosis refractory to conventional therapies, even when transthoracic echocardiography is inconclusive. Contrast echocardiography with agitated saline may serve as a valuable adjunct when diagnostically evaluating this condition.

Author Contributions

Conception and design of the research and Data analysis and interpretation: Faria TIL, Amaral F, Sgarbieri RN, Manso PH; Data collection: Faria TIL, Sgarbieri RN, Manso PH

Manuscript drafting: Faria TIL, Amaral F, Manso PH; Critical revision of the manuscript for important intellectual content: Amaral F, Sgarbieri RN, Manso PH.

Potential Conflict of Interest

No potential conflict of interest relevant to this article was reported.

Sources of Funding

There were no external funding sources for this study.

Study Association

This study is not associated with any thesis or dissertation work.

Ethics Approval and Consent to Participate

This study was approved by the Ethics Committee of the Hospital das Clínicas da FMRP-USP under the protocol number CAAE: 95110926.9.0000.5440. All the procedures in this study were in accordance with the 1975 Helsinki Declaration, updated in 2013. Informed consent was obtained from all participants included in the study.

Use of Artificial Intelligence

The authors did not use any artificial intelligence tools in the development of this work.

Availability of Research Data

All datasets supporting the results of this study are available upon request from the corresponding author.

References

1. Galli MA, Galletti L, Schena F, Salvini L, Mosca F, Danzi GB. A Rare Case of Neonatal Cyanosis Due 'Cor Triatriatum Dexter' and a Review of the Literature. J Cardiovasc Med. 2009;10(7):535-8. doi: 10.2459/JCM.0b013e32832a574f.
2. Sunthankar S, Do NL, Parra D, Vera K, Soslow JH. Mysterious Infantile Cyanosis: An Imaging Case Series. CASE. 2021;5(5):267-72. doi: 10.1016/j.case.2021.07.013.
3. Kalangos A, Shatelen N, Demyanchuk V, Ruban N, Sfyridis P, Todurov B. Cor Triatriatum Dexter in Children: Literature Review and Case Report. JTCVS Tech. 2020;4:254-8. doi: 10.1016/j.xjtc.2020.08.024.
4. Alghamdi MH. Cor Triatriatum Dexter: A Rare Cause of Cyanosis during Neonatal Period. Ann Pediatr Cardiol. 2016;9(1):46-8. doi: 10.4103/0974-2069.171408.
5. Caputo A, Giordano M, Iacono C, Oppido G, Russo MG. A Rare Cause of Cyanosis in Neonatal Age: Cor Triatriatum Dexter. Ann Pediatr Cardiol. 2022;15(4):429-30. doi: 10.4103/apc.apc_173_21.
6. Picciolli I, Francescato G, Colli AM, Cappelleri A, Mayer A, Raschetti R, et al. Cor Triatriatum Dexter: Contrast Echocardiography is Key to the Diagnosis of a Rare but Treatable Cause of Neonatal Persistent Cyanosis. Children. 2022;9(5):676. doi: 10.3390/children9050676.
7. Smith K, Makhoul M. Out of Sight, but Still Should Be in Mind. CASE. 2022;6(2):87. doi: 10.1016/j.case.2021.12.007.

This is an open-access article distributed under the terms of the Creative Commons Attribution License